

# Original Work

## New method for the treatment Of pudendal neuralgia

212 cases and 104 decompression surgeries

E. Bautrant\*, E. de Bisschop\*, V. Vaini-Elies\*, J. Massonnat\*\*,  
I. Aleman\*\*\*\*, J. Buntinx\*\*\*, J. de Vlieger\*\*\*, M. Di Constanzo\*\*\*,  
L. Habib\*\*\*\*, G. Patroni\*\*\*\*, S. Siboni\*\*\*\*\*, B. Ceas\*\*\*\*\*, V.  
Schiby\*\*\*\*\*, M. Uglione-Ceas\*\*\*\*\*

\* *Centre Liberal Aixois de Rehabilitation Pelvi-perineale, Le Grand Angle, 4, place Barthelemy Niollon, 13100 Aix-en-Provence.*

\*\* *Service de Radiologie Interventionnelle, Clinique Axiom, 13090 Aix-en-Provence.*

\*\*\* *Service d'Anesthesie, Clinique Axiom, 13090 Aix-en-Provence,*

\*\*\*\* *Service d'Anesthesie, Clinique Saint-Jean, 13105 Mimet.*

\*\*\*\*\* *Service de Reeducation Perineale, Clinique Axiom, 13100 Aix-en-Provence.*

### **SUMMARY: Modern algorithm for the treatment of pudendal neuralgia: 212 cases and 104 decompressions.**

Clinical signs and symptoms of pudendal neuralgia are very rich, with a great individual variability. The clinical diagnosis is difficult. It is confirmed or invalidated by electrophysiological tests. Since October 1998, patients' selection has been possible using a diagnosis score. Over a four-year period, the diagnosis of pudendal neuralgia was confirmed by electro-physiological investigations on 212 subjects. We rejected 12 patients because of a radiculo-medullary organic etiology. We only describe here cases of women with a peripheral pudendal nerve injury (200 patients). Thirty-eight neuropathies free of canal symptoms (obstetrical, post-traumatic...) were treated by injection therapy. The study of a total of 162 canal syndromes showed prevalent injury at the sacro-spino-tuberal ligament grip which was observed in 68% of the cases, compared to the Alcock canal which was present in only 20% of the cases. One hundred four of these patients underwent surgical decompression via a trans-ischio-rectal approach after negative results of the infiltration therapy. We report here the surgical methodology, the post-op follow-up and the results, which appears quite successful: after one year the subjects are symptom-free or have a significant reduction in pain.

**Key words:** *Pudendal nerve ● Entrapment syndrome ● Alcock canal ● Sacro-spinal-tuberal ligament ● Surgical decompression*

Errata :

1 At the end of the summary (last sentence), add “86 % of”:

.... wich appears quite successful : after one year **86% of** the subjects are symtom-free or have a significant reduction in pain .

2 Page 8: TREATMENT OF THE CANAL SYNDROME ( 162cases): add “86 %” :

After 1 year ( T12 ) , 53/63 patients (**86%**) are AS or RS 38/62 (62%) are totally asymptomatic .

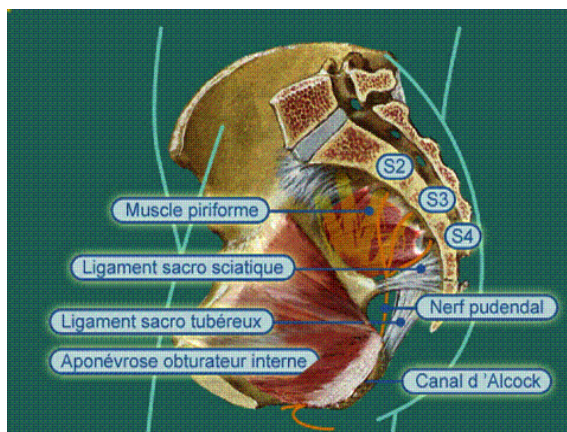


Fig 1 Risk area of the pudendal nerve

The perineal pain and pelvic-perineal in relation to the pudendal nerve neuralgia appears currently largely underestimated.

Since the original work of Amarenco [1], Shafik [2], Turner [3] Robert et al. [5] many patients were finally told the origin of their pain, unfortunately quite old and very incapacitating. The pudendal nerve (n.pudendus) may be submitted to many forms of trauma along its course either inside or outside the spine (fig.1) If the medullary or radiculo-plexus conflict can be at the origin of perineum neuralgia of the pudendal type by neurological pathology or lombo sacral [6], the progress and neurological and physiological exploration of the perineum allow us to distinguish from the impairment to the pudendal nerve itself [7].

With a set of 212 patients affected by some form of pudendal neuralgia, this work is only about pudendal neuralgia and its branches, either by canal compression syndrome or by mono-neuropathy and this to show the specificity and frequency of this pathology in gynecology.

Finally, we will discuss the clinical specificity and physio-pathological and the therapeutic possibilities and in particular the trans-vaginal decompression.

## ■ Anatomical data

The anatomy of the pudendal nerve is complex but its knowledge is critical to understand the different conflicts that until the end of the 1990s were only concentrated on the Alcock canal [1, 2, and 11]. It is the dissection in the anatomy laboratory that allows us to understand each segment of the nerve route and its branches. Its anatomy has been particularly studied by Shafik, who insists on the fact that the nerve has a dual mode, sensitive and autonomic [8-10] Starting from the medullary segment S2-S4, the axons creep all the way to the muscles in the pelvic floor following the ventral roots of the marrow, the rachidian nerves, the "horse tail", the sacred trunk and the nerve itself. We describe the three segments of the pudendal nerve [12], the path of its branches and the nerve terminations [13, 14] and finally, the gynecology aspect and the relation to the vagina.

## The three segments of the pudendal nerve (fig 2)

The first segment corresponds to its origin and the pre-sacral region where it starts mainly from the third sacral root and gets contingents from underlying and overlying S2 and S4 with a lot of anatomical variations without a contribution from S1 or S5 [15]

The second segment corresponds to the infra-piriformis canal. Right after it starts; the nerve penetrates the gluteal region under the piriformis muscle and bypasses truly the end of the sacro-spinal ligament. It is then in contact with the face of the sacro-tuberal ligament. It is at this location that the ligament behaves like a clamp. The phenomenon of scar sclerosis of the sacro-spinal ligament is squeezing the nerve against the sacro-tuberal ligament. Among our patients, it is where we encountered the most pudendal canal syndromes.

- The third segment corresponds to the pudendal canal so called the Alcock canal [16]. After going around the sacro-spinal ligament ending, the nerve is going under the elevator muscle of the anus (m.levator ani), along the ischial tuberosity (tuber internus ischidicum), and a split of the fascia of the obturator internis (m. obturatorius) which forms the Alcock canal.

Here again, the phenomena of fibrosis retraction can squeeze the nerve against the bone relief, in particular at the exit from the ischion canal, but as well by scar retraction of the elevator muscle of the anus or the falciform extension of the sacro tuberal ligament.

At all levels, the nerve can be compressed, stretched or be subjected to the noxious effect of impairment.

### **The path of the branches and nerve terminations [13,14]**

The anatomy of the nerve terminations is very complex and has many variations. However, it is the knowledge of the sensitive innervated area that allows linking the pain to its pudendal origin. A systematic review of the three terminal branches of the pudendal nerve is proposed to allow for a thorough understanding and despite the very complex path of the nerve terminations and variation among individuals.

#### *Rectal inferior nerve (n.rectales inferiors)*

It begins mainly in the Alcock canal for the majority of cases. Its sensitive branches involve the anal canal, the caudal third of the rectum, the skin of the posterior vulva fork and peri-anal with inconsistent cutaneous perineal dorsal terminations. Its muscle motor branches are terminated at the anus elevator level and in the external sphincter of the anus.

#### *Perineal nerve (n. perineales)*

It starts from the pudendal nerve at the exit of the Alcock canal. Its sensitive branches involve the inferior third of the vagina and of the urethra as well as the lips. Its motor branches cross the ventral perineal membrane and end in the striated sphincter of the urethra.

#### *Dorsal nerve of the clitoris (n.dorsalis clitoridis)*

It begins as well at the exit of the Alcock canal. Two branches are distinct. The clitoris branch at the pubis branch with the unique feature of having terminations beyond the pubis arcade all the way to the inguinal

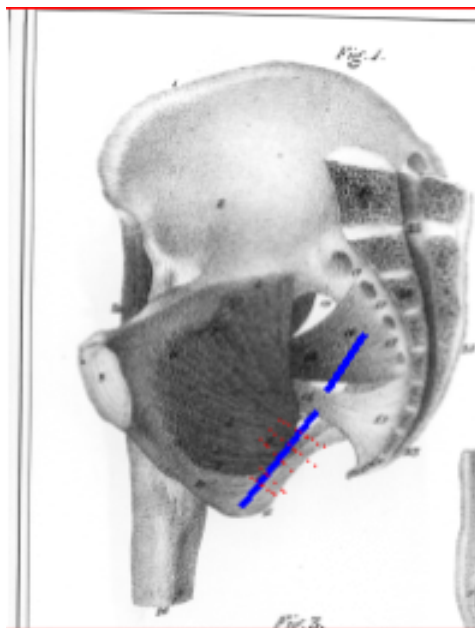


Fig 2 The three segments of the pudendal nerve

Channel. Those inconsistent terminations can explain some inguinal pain symptoms and even of the lower iliac cavity.

### **Relation to the Vagina**

The vagina has a relation to the three segments of the pudendal nerve. It represents therefore a very interesting way for surgical decompression of the pudendal nerve. In its lower third, it corresponds to the vertical segment, the vagina is separated from the Alcock canal by the elevator muscle of the anus that we will have to push aside. In its upper two third it corresponds to the horizontal segment, the vagina is in contact with the sacro-spinal and thus with the infra piriformis and the second segment of the pudendal nerve seat of the ligament grip. Above, the relation is pursued by the short pre-sacral segment.

### **Material and method**

From October 1998 until April 2002, 212 female patients have been diagnosed with a symptom of pudendal neuralgia. The median age was 52 years of age varying from 19 to 81 years.

## The diagnostic

It is a neuropathic pain, often burning, irradiating, sometimes like a lightning, continuous or striking with a great intensity. The major criterion for diagnostic is the pain location in one or several zones covered by the pudendal nerve terminations.

If the peri-anal, rectal, vaginal, labial, urethral, clitoridian pain, isolated or combined depending on the case steers us to the pudendal origin. Sometimes pain of an irradiating nature under the pubis and inguinal in the distal territory of the dorsal nerve of the clitoris can be misleading.

It explains the long journey of many patients before a proper diagnostic. Close to 90% of the patients were previously mis-diagnosed having received gynecological, urological, radiological or digestive investigations. Similarly 37% of the patients had surgery from laparoscopy, inguinal hernia, ovarian cyst surgery and even hysterectomies. Those operations having sometimes increased the neuralgia.

The pain can sometimes be reproduced by pressure in the pelvis on the path of the pudendal nerve demonstrating a real Tinel's sign. This examination method allows for finding the anatomical site of the problem.

Another criterion is an increase in pain when sitting, the existence of an etiological factor or a trigger.

Regarding this subject, the pudendal neuralgia can be the consequence of a pelvic

or perineal operation (hysterectomy, treatment of a prolapse, or urinary incontinence), an exploration of the cavity (colonoscopy, cystoscopy), a trauma. Our experience shows us that those events are factors in the decompensation of a preexisting pudendal nerve problem (congenital canal syndrome?) instead of the main etiology.

Finally the positive response to the injection of a local anesthetic (lidocaine) is one of the major criteria of diagnostic. We will see that it gives a good prognosis for the decompression surgery.

The set of all those points can be summarized as a score (table 1)

## Electrophysiological exploration [17-21]

Those electrophysiological investigations are based on the electromyographic puncture of the muscles innervated by the pudendus nerve (pelvic floor, sphincter streaked and anal sphincter), distal motor conduction by stimulation of the endocavity, the recording of the sacral reflex and the suggested potential somesthetic spinal and cortical.

The investigation is completed if necessary by a radicular EMG of the inferior limbs.

Therefore, we can after this electrophysiological summary:

-confirm the pudendal neuropathic pain, meaning to know the level and type of nerve damage (medullated, axon)

**Table I** Diagnostic score: 1 major criteria + 2 Minor criterion or major criteria

Major criteria	Minor criteria
1 Painful area in the pudendal nerve path terminations - Nerve rectal inferior: anus, peri-anal, lower third of the rectum, buttock - Perineal nerve: small lips, big lips, inferior third of the vagina, peri-urethra - Dorsal nerve of the clitoris, pubic symphysis 2 Reproduction of pain on pushing on the pudendal trunk (equivalent to the Tinel sign) and anatomical localization of the affected area 3 Successful injection of the anatomical site (major criteria). - Lidocaine injection - Significant improvement or sedation of the pain for > 12 hours.	1 Neuropathic pain sensation 2 Existence of a painful position and/or antalgic (worse when sitting, better in decubitus) 3 Existence of an etiological factor or of a trigger event -Etiology: obstetrical, trauma - Trigger event: surgery, perineal operation or other 4 Lack of another painful cause in the pelvic area - Pelvic endometriosis or recto-vaginal - Uterine adenyomosis - Complex Uterine fibroma - Under urethra cyst

- Elimination to the radicular and medullar origin. Twelve patients have been rejected because of pudendal neuralgia of the "high" type.

- Compression phenomena or a mono-neuropathy. Among the 200 patients that present a truncular problem of the pudendal nerve, we are recording 38 mononeuropathies and 162 canal syndrome (*Table II*)

- Localization of the anatomical conflict at the ligament clamp and/or the Alcock canal, The distinction is based on the sacral reflex (RS), on the motor distal latency test (LDM) done under the sciatic spine and on the tibial nerve. The five early latencies are studied and used.

In case of doubt, we are using the late response R2 of the sacral reflex et the amplitude ratio R1/R2, R1 being the first response of the sacral reflex.

The results are summarized in *table III*. Among the 162 canal syndromes, the compression at the ligament grip was found in 68% of the cases and in the Alcock canal in 12% and in both locations in 20%.

The compression at the Alcock canal is therefore not the most frequent and our observations demonstrate that the ligament grip is responsible for close to 90% of the cases which has important surgical and therapeutic consequences.

### ■ Decompression technique of the pudendal nerve

Shafik is the first to have attempted the decompression of the pudendal nerve [22-25] by using a perineal para-anal path. The guiding factor of the dissection is the rectal nerve inferior of the Alcock canal. The freeing of the canal is realized but access to the ligament squeeze which is the most frequent area of the canal syndrome is difficult if not impossible this way.

Robert [26] by its trans-gluteal way and then Mauillon et al. [27] approach by the dorsal

**Table II** Oct 1998 to Oct 2002: 212 cases of pudendal neuralgia

12 radicular suffering intra-spinal of the pudendal nerve between L2 and S1 (5.7%)

200 truncular affection  
-38 mononeuropathies (19%)  
-162 canal syndromes (76.4%)

110 ligament clamp (68%)  
65 bi-lateral

50 Alcock canal: 20%  
15 bilateral (30%)  
The 2 locations: 20%

**Table III** Localization of the anatomical conflict at the ligament clamp and/or Alcock canal.

RS	LDM	PES Spinal stimulation Dermatoma	PES Spinal stimulation endo-cavity	Ligament clamp	Alcock canal
↑	-	↑	↑	↑	0
↑	↑	↑	-	0	↑
↑	↑	↑	↑	↑	↑

**↑ Delayed; - normal level; 0 no compression**

path the ligament grip after cutting the sacro-spinal ligament to free the ligament grip and the pudendal nerve at the under-piriformis canal. Access to the caudal segment of the Alcock canal is less easy.

Since 1998, we approach the three segments of the pudendal nerve by the ischio-rectal trench. Entering this avascular space is done with a woman by going through the vagina (104 cases) and with a man by the rectal anterior divide of the rectum (7 cases). The dissection of the ischio-rectal trench allows exposing the medial face of each pelvis side after having pushed the rectum inside. The objective of the operation is uniquely a decompression of the location(s) involved in the canal syndrome.

There is therefore no neurolysis and no dissection

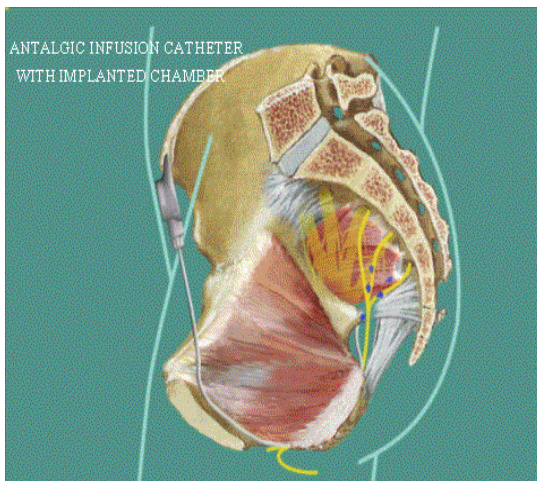
close to the nerve, which prevents any de-vascularization or further fragilization of the nerve post surgery that already shows obvious damages.

The decompression surgery starts always by opening the under-piriformis canal, at the inferior side of the sacro-spinal ligament. Once the perinervous fat of the canal is reached, the decompression goes towards the compression area (fig 3).

In 90% of the cases, the complete section of the sclerosed fibers of the sacro-spinal ligament is done to allow freeing the ligaments grip from bottom to top. The section of the indurated fibers squeezed against the pelvis is impressive and explains the intensity of the canal syndrome. This dissection is done under careful endoscopy and after very careful and progressive hemostasis with bipolar energy.

The operation can be pursued caudally when necessary, by cutting the sclerosed fibers of the falciform extension of the sacro-tuberal ligament until penetrating the Alcock canal. At this stage, the finger can explore the entire Alcock canal and can finish by "digitoclasie" (digit=finger) the decompression by making sure that the entire pudendal canal is free.

This method appears to us ideal for managing the truncular canal syndrome of the nerve for three main reasons:



**Fig 3** Decompression of the ligament grip via a transischio-rectal approach.

-It is the only way which allows to access to the three segments of the pudendal nerve and in particular the ligament clamp, seat of the majority of the compressions.

-The decompression and section involve exclusively the pathological ligament fibers (location of an intense fibrosis confirmed by anatomical-pathology) which grips the pudendal nerve against the pelvic osteo-ligament. The other perineal or ligament tissues are untouched.

- The painful post-surgery phenomena are reduced by the lack of scar despite the severity of the operation. However, in 38% of the cases of our surgery, a very intense post-surgery pain of the buttock, different from the nerve pain has been reported. That pain can be linked to the section of the sacro-spinal ligament and linked as well to the abundance of nervous network of some ligaments. The pain decreases during the first month to disappear progressively but eventually goes away completely.

## Post-surgery and Complications

### *Post surgery follow-up*

The operation ends always by putting in place a catheter for antalgic infusion in the tunnelised pudendal canal all the way to the under-pubic level. This catheter allows insuring an efficient post-surgery antalgia; it is removed after the 3<sup>rd</sup> or 4<sup>th</sup> day.

Starting a year ago, when the neuralgia is important, and/or old which makes us suspect that there may be residual neuralgia for the next 10 months, the catheter is connected to an implanted site; it is used in case of neuralgic discharges during the nerve regeneration period that can spread from 6 to 18 months.

The hematomas are prevented routinely by drainage of the ischio-rectal cavity for 48 hours. A probe is inserted at the beginning of the operation so that the surgery can be performed with a perfectly empty bladder; it is removed the day after surgery.

The departure from the surgery department is done at Day3 or Day4 and patients can be sent home; they can also be ideally



transferred to the recovery department so that they can benefit, in addition to analgesic physical therapy, of a re-education based on perineal consequences. The objective being to obtain the most complete recovery from a multi-disciplinary team.

### *Complications*

#### Infection complications

Eight low urinary infections have been recorded (7%) and treated efficiently by urinary antiseptic. Three abscess of the ischio-rectal area (2.5%) have been treated by secondary evacuation and drainage at Day7, Day8 and Day9; for those three patients, the complication was not a problem because they were among the patients that had seen their neuralgia disappear.

#### Hemorrhagic complications

They are linked to the important artery network in that area. The hemostasis must be done very carefully and rigorously with a perfect knowledge of the artery system of the branches of the ventral and dorsal trunk of the internal iliac artery.

We are using bipolar energy for the totality of the hemostosis.

However, we report an injury of one branch of the internal pudendal artery and a false secondary aneurysm of a branch of the cranial gluteal artery. The injury of the branch of the internal pudendal artery was translated in peroperative bleeding; the control of the hemostosis was obtained peroperatively and the blood loss was quickly compensated by using a "Cell-saver". There was no transfusion. The false secondary aneurysm of the branch of the cranial gluteal artery started suddenly at Day 15 and again 48 hours later and treated by radiology operation (embolization) during a 72 hour hospitalization; again, there was no need for transfusion.

## ■ Indications and Results

### Methodology

The evaluation of the results on pain is complex and subjective; it is the reason why we chose to express them by an elementary methodology. The results on pain are evaluated by the VAS scale (Visual Analog Scale) in comparison with pre-surgery pain.

Good results correspond to asymptomatic patients (AS) or presenting a satisfying and significant reduction in pain (RS) with a VAS inferior by 50% to the original value.

### Treatment of the canal syndrome (162 cases)

It includes always in a first time a series of 1 to 3 injections associated with the administration of Clonazepam.

Fifty-eight patients (36%) are asymptomatic (AS) or experience a satisfying reduction in pain after injections.

For patients facing a persistent neuralgia, decompression surgery is proposed.

One hundred and four patients (10 females and 7 males) benefited from our decompression technique using the trans-ischio-rectal way 6 months ago for 80 patients and 1 year for 62 among them.

Right after surgery (T0) 43/104 patients (41%) report an immediate pain disappearance. At 6 months, (T6), 53/80 patients (66%) are asymptomatic or are satisfied with their pain reduction.

After 1 year (T12), 53/62 patients are AS or RS 38/62 (62%) are totally asymptomatic.

Among 18 patients, with whom the prognostic of nervous regeneration was initially low, a site of analgesic infusion, with the catheter in the pudendal canal was put in place at the end of the surgery. This allows the management of residual neuralgia or the pain strikes that can happen during the nerve regeneration period of 9 to 24 months.

### Neuropathic treatment (38 cases)

We were able to determine the original trauma among 29 patients. For 12 patients, the neuralgia followed labor. Regarding the other patients, for another 10, the trauma was due to a fall or a direct hit and 7 in post surgery.

We have recorded 3 patients spontaneously cured and another 1 by taking low doses of Clonazepam. The other patients were treated with a series of 1 to 3 injections. The injections are done in collaboration with the surgery team in a trans perineal fashion and under simple anatomical guidance allowing for better efficiency and simplicity. Thirty five patients have seen their pain disappear totally looking back 6 months. The 12 neuropathies after labor are asymptomatic.



## ■ Conclusion

Pudendal neuralgia is a particularly incapacitating affection. A part only of its physio-pathological mechanism can be explained; many points are still mysterious; the treatment describe here is complex and requires the collaboration of a multi-disciplinary team.

The decompression surgery by the ischio-rectal way gives very interesting results (86% after 1 year). It requires however a very good surgery practices with a team ready to deal with post-surgery care.

## ■ References

1. Amarenco G Lanoe Y, Gouda1 H Perrigot M. La compression du nerf honteux interne dans le canal d'Alcock ou paralysie perineale du cycliste. Un nouveau syndrome canalair. Presse Med 1987 ; 8: 399.
2. Shafik A. Pudendal canal syndrome. Description of a new syndrome and its treatment. Report of 7 cases. Coloproctology 1991; 73 102-10.
3. Turner MLC, Marinoff SC. Pudendal neuralgia. Am J Obstet Gynecol 1991; 765 1233-6.
4. Robert R, Labat JJ, Lehur PA, Glemain P, Armstrong O, Le Borgne J, et al. Reflexions cliniques, neurophysiologiques et therapeutiques & partir de donnees anatomiques sur le nerf pudendal (honteux interne) lors de certaines algies perineales. Chirurgie 1989 ; 75 : 515-20.
5. Beco J, Mouchel J. Inter& de la decompression du nerf pudendal pour le chirurgien perindologue. Gunai'keia 1997;2: 44-7.
6. de Bisschop GI de Bisschop E. Le ned normal et pathologique : repercussions electrophysiologiques. In Beco J, Mouchel J, Nelissen G. La perineologie. Comprendre un equilibre et le preserver. Verviers : Odysse 1372, 1998 ; 70 : 1-19.
7. Amarenco GI Kerdraon J. Syndrome du canal d'Alcock et nevralgies perineales. Lyon Chir 1993 ; 89 : 179-82.
8. Shafik A, El Sherif L, Youssef A, Olfat E. Surgical anatomy of pudendal nerve and its clinical implications. Clin Anat 1995;
9. de Bisschop EI de Bisschop G. Un syndrome peu connu en medecine du sport : le syndrome du canal d'Alcock. Med Sport 8: 11 0-5. 1998 ; 72 147-51.
10. de Bisschop G, Dumoulin J. Electromyographie clinique Paris Masson, 1992.
11. Juenemann KP, Lue TF, Schmidt RA, Tanagho EA. Urological neurology and urodynamics. Clinical significance of sacral pudendal nerve anatomy. J Urol 1988; 739 74-80.
12. Robert MI Labat J.J, Bensignor MI Szapiro J, Faure A, Martin Costargent A. Bases anatomiques de la chirurgie du nerf pudendal. Lyon Chir 1993 ; 89 : 183-7.
13. Shafik A, Doss S. Surgical anatomy of the somatic terminal innervation to the anal and urethral sphincters: role in anal urethral surgery. J Urol 1999; 67: 85-9.
14. Hollabaugh RS, Steiner MS, Sellers KD, Samm BJ, Dmochowski RR. Neuroanatomy of the pelvis. Dis Colon Rectum 2000; 43: 390-7.
15. O'Bichere A, Green C, Phillips RKS. New simple approach for maximal pudendal nerve exposure: anomalies and prospects for functional reconstruction. Dis Colon Rectum 2000; 43: 956-60
16. Shafik A, Doss S. Pudendal canal: surgical anatomy and clinical implications. Am Surg 1999; 65 176-80.
17. Amarenco G, Kerdraon J, Albert T, Denys P. Neuropathie d'etirement du nerf honteux interne. Ses relations avec l'incontinence urinaire, les troubles ano-rectaux et genito-sexuels de la femme. Contracept Fertil Sex 1994 ; 22 : 235-
18. Robert R, Labat JJ, Lehur P.A, Glemain P, Armstrong Borgne J, Barbin JY. Reflexions cliniques, neurophysiologiques et therapeutiques a partir de donnees anatomiques, sur le nerf pudendal (honteux interne) lors de certaines algies perineales. Chirurgie 1989 ; 75 : 515-20.
19. Galaup JP. Dyschesie, neuropathie pudendale et troubles fonctionnels pelvi-perineaux. Progr Urol 2000;
20. de Bisschop GI de Bisschop EI Commandre F. Les syndromes canalaires. Paris Masson, 1997.
21. de Bisschop E. La participation radulaire et vertebrale dans certains dysfonctionnements du nerf pudendus. A propos de 456 explorations. ile Maurice SIFUD, 2000.
22. Shafik A. Pudendal canal decompression in the treatment of idopathic fecal incontinence. Dig Surg 1992; 9: 265-71.
23. Shafik A, Pudendal canal decompression in the treatment of urinary stress incontinence. Int Urogynecol J 1994; 5: 215-2
24. Shafik A. Endoscopic pudendal canal decompression for the treatment of fecal incontinence due to pudendal canal syndrome. J Laparoendos Adv Surg Tech 1997; 7: 227-34.
25. Shafik A. Pudendal canal syndrome as a cause of vulvodynia and its treatment by pudendal nerve decompression. Obst Gynecol Reprod Biol 1998; 80: 215-20.
26. Robert MI Brunet C, Faure A, Lehur PA, Labat JJ, Bensignor M et al. La chirurgie du nerf pudendal lors de certaines algies perineales : evolution et resultats. Chirurgie 1993-1994 119 535-9.
27. Mauillon J, Thoumas D, Leroi AM, Freger P, Michot F, Results of pudendal nerve neurolysis-transposition in 12 patients suffering from pudendal neuralgia. Dis Colon rectum 1999; 42 186-92.